

Issue 2 Optimising Combination Therapy

Authors:

Dr Rafael Serena and Dr Artur Carbonell, Barcelona, Spain

April 2005

EDITORIAL

Today, as you all well know, non-invasive facial rejuvenation treatments not only rely on the central role of botulinum toxin but, more importantly, on its judicious combination with other popular techniques. 'Optimising Combination Therapy' by Drs Serena and Carbonell is the second issue in our series entitled 'Expert Approaches to using Botulinum Toxins' and appropriately deals with the essential practicalities of how to use botulinum toxin in conjunction with other commonly used procedures in a non-invasive aesthetic practice.

The authors start by reviewing the main clinical studies that have re-inforced commonly accepted practice in that combining botulinum toxin with fillers not only improves the desired correction but also significantly prolongs the cosmetic results. It is followed by succinct summaries describing ablative laser resurfacing, non-ablative remodelling, Intense Pulsed Light, peels and facial surgery considerations. In addition, keeping to the stated goal of remaining practical, a detailed outline of when and how to combine botulinum toxin to these aforementioned procedures is discussed.

I hope that their suggestions will assist you in planning successful combination treatment and help you further improve on your results.

Dr Phillip Levy, Geneva, Switzer

USING A SYNERGISTIC APPROACH

No single cosmetic procedure can be expected to reverse all the unwanted signs of photo- or chronologic-ageing of the face. However, a growing body of scientific studies coupled with recent clinical experience show that combining botulinum toxin treatment with other techniques synergistically enhances, refines and may even prolong the effects that can be achieved with any procedure alone.

The key signs of chronologic ageing of the face are either dynamic changes (eg. rhytids arising from hyperfunctional muscular activity) or static changes, such as atrophy of underlying soft tissue, sagging and certain superficial wrinkles.

Most patients seeking facial rejuvenation treatment have both dynamic and static signs of ageing. It is, therefore, a logical approach to combine various treatment modalities to address these different needs.

Whatever combination is ultimately chosen, the aim of treatment should preferably be, in our opinion, for a subtle, natural look that leaves patients looking refreshed rather than changed. To achieve this requires both careful assessment of each patient's particular facial anatomy in both dynamic and static positions as well as a detailed discussion of their needs and expectations. Equally as important is the physician's recommendation of which combination of treatments to use, and in which order they should be given.

In this succinct position paper we will present a synopsis of the most popular therapies commonly used to treat the photo-ageing and chronologically-ageing face.

Botulinum toxin treatment provides effective, reversible chemodenervation resulting in softening and relaxation of facial wrinkles. Because of its unique mechanism of action, simplicity, ease of use and safety, adjunctive use can be considered with every other treatment modality.

COMBINING BOTULINUM TOXIN WITH...

■■■■■■■■■■

Fillers

Before the introduction of botulinum toxin, fillers were widely used on their own for the treatment of glabellar 'frown' lines, arising from contraction of the corrugator muscle complex. While they can reduce such wrinkles, fillers do not address the underlying cause and the continued frowning eventually puts mechanical pressure on the biodegradable polymers placed into the glabellar rhytids, resulting in premature breakdown and subsequent loss of effect [1].

It is now widely accepted that combining botulinum toxin type A with fillers produces superior results. Patients are more satisfied with both the immediate and longer term aesthetic results, and it is shown that the desired effects last longer [2,3].

In a recent study, the combination of botulinum toxin and a hyaluronic acid filler was shown to achieve a better response than non-animal sourced hyaluronic acid (NASHA) treatment alone [2]. Thirty-eight women with moderate to severe glabellar lines had botulinum toxin injections into their corrugator and procerus muscles followed by NASHA treatment one week later, or NASHA alone.

Throughout the 32 week follow-up, more women who had combination treatment had improved scores on the facial wrinkle scale, at rest and full muscle contraction, than those who had NASHA alone. In addition, the benefits of treatment were longer lasting. The median time for return to pre-injection furrow status was 18 weeks for the women who had NASHA alone, compared with 32 weeks for those who had combined botulinum toxin and NASHA treatment.

In another study of 65 patients with moderate to severe glabellar furrows, an independent physician recorded significantly greater improvement in glabellar lines one month and greater persistence of results three months after combination treatment with botulinum toxin and a collagen filler, than was achieved with either treatment alone [3]. Botulinum toxin and collagen treatment were administered during the same treatment session.

A further consideration in the combined use with fillers is indeed the choice of filler from the many available products. The most important distinction is between resorbable and non-resorbable products. A word of caution concerning the non-resorbable ones: a permanent filler will in some cases produce a permanent, undesirable side effect which could eventually be cosmetically and psychologically disastrous. Keep in mind that resorbable fillers, such as the popular hyaluronic acids, have different sources, manufacturing processes and particle sizes aimed at different depths of wrinkles. The selection of the individual filler depends on the patient's requirements, the duration of correction needed and full appreciation of potential side effects.

Ablative Laser Resurfacing

Carbon dioxide (CO₂) and erbium: YAG lasers have been widely used for ablative skin resurfacing since the mid 1990s.

Using botulinum toxin as an adjunctive treatment to laser resurfacing can improve results by decreasing mechanical disruption of the healing process, thus enabling improved collagen remodeling following the laser treatment. Combined treatment with botulinum toxin-A is especially useful for the crow's feet, peri-oral and forehead areas. Injecting botulinum toxin prior to laser treatment has been shown to not only improve overall results but also aid the healing process. In all cases, botulinum toxin used as regular maintenance therapy will prolong the smoothing, wrinkle reduction effects.

Non-Ablative Laser Remodelling

Ablative laser resurfacing often produced a lengthy and uncomfortable post-surgical healing period. In order to avoid the important and sometimes irreversible side effects, new approaches to generating collagen synthesis and skin tightening were sought. Specific new non-ablative collagen remodelling lasers were thus developed (e.g. 1320nm, 1450nm and 1540 nm) and certain existing lasers were tested with new non-ablative treatment protocols (e.g. erbium-YAG, ND-YAG, Q-switched, pulse-dye lasers). A more recent remodelling procedure concerns radiofrequency technology. Various machines using different parameters claim to tighten skin and stimulate collagen synthesis by selective thermal damage. Presently the protocols are changing in order to eliminate certain significant side effects encountered with initial treatment models.

In all cases the combination therapy of botulinum toxin and collagen remodelling technology both improves and prolongs the cosmetic, smoothing results.

Intense Pulsed Light (IPL)

A particular form of non-ablative photo-rejuvenation treatment is IPL - a high intensity pulsed light treatment that is used primarily to treat UV-induced mottled pigmentation, telangiectasias and diffuse erythema. At ce

that is used primarily to treat UV-induced melasma pigmentation, telangiectasias and diffuse erythema. At 500-600 nm wavelengths IPL can also stimulate collagen and elastin synthesis [5].

In addition to treating sun damaged skin the technique is being used increasingly to soften lines around the eyes and overall to make the skin look 'fresher'. Clinical data suggests that the best results can be achieved when IPL is combined with botulinum toxin injections [5].

In a recent study, patients who had combination treatment with botulinum toxin and IPL had greater improvement in crow's feet lines in the periocular area than those who just had IPL alone [5].

In our experience this is an ideal technique to combine with botulinum toxin as the botulinum therapy synergistically enhances the IPL rejuvenating results.

Peels

Chemical peels are defined as applications of acids to the skin which produce a controlled injury followed by the wound healing process which ultimately produces a smoother, more youthful appearance. Benefits may include improved skin colour, brightness, surface texture, tone and possible wrinkle reduction.

We can classify chemical peels into superficial, medium and deep, depending on the depth of action. These vary from lower concentration prolonged contact hydroxy acid moisturisers to higher concentration, short contact skin peeling agents. Glycolic acid is the most frequently used product for superficial skin peeling but other common peels in this category include salicylic acid, Jessner's solutions and mild TCA peels. Deep peeling is usually achieved by various high strength TCA combinations or a phenol-based agent.

Botulinum toxin is used most effectively 1-2 weeks prior to the peeling procedure in order to treat glabellar frown lines, crow's feet, or deep lines around the mouth, providing a smoother skin prior to a generalised facial peel [6]. In the post-treatment phase, botulinum toxin provides a highly effective maintenance therapy to inhibit the formation of new wrinkles.

Facial surgery

Botulinum toxin and surgery have complementary effects on the ageing face. While botulinum toxin addresses the dynamic changes associated with facial muscle activity, surgery corrects the effects of loose, sagging or atrophied tissue. While surgery tends to focus on pulling up sagging cheeks, lifting eyebrows or removing excess tissue from around the eyes, botulinum toxin injections smooth out lines and wrinkles around the eyes between the eyebrows and around the mouth.

Recent reports have suggested that botulinum toxin can be usefully employed to reduce the tension exerted on the skin by the healing process, resulting in reduced scarring.

We recommend that patients have their botulinum injections when they come to clinic to have their stitches - about a week after surgery.

These timings are less critical if patients are having the toxin and surgical treatments in different parts of the face. For example, if they are having surgery to the lower part of their face, botulinum injections can be carried out at the same time in the forehead.

IMPROVING OUTCOMES

It is important to ascertain what procedures patients have previously had, and how recently. All too often, patients

present at clinic requesting, for example, a botulinum toxin treatment within only a few weeks of a previous procedure at another clinic. In some cases, they have been dissatisfied with the results or may not have waited for the effects to fully develop. Care should specifically be taken where patients have had "unidentified" fillers to ensure prevention of future adverse reactions.

Presentamos la técnica descrita para tratar diferentes inestetismos en una serie de casos reflejados.

MAKING TREATMENT DECISIONS (EXAMPLES)

Glabellar and forehead region

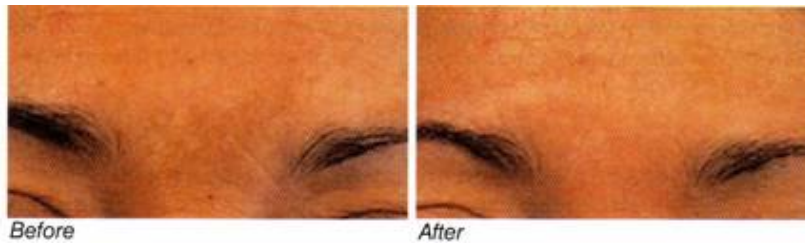The choices facing the practitioner in the glabellar and forehead region are dependent not only on the wrinkles in this area but the shape and location of the eyebrows, the general appearance of the skin and any apparent photodamage. The considerations are as follows:

procedure. The considerations are as follows.

- What improvements could be made to the texture and coloration of the skin? Consider topical retinoids, a peel dependent on the depth of any discoloration, or laser resurfacing.
- Are glabellar/forehead wrinkles dynamic? Consider botulinum toxin type A injections.
- Are the wrinkles still apparent at rest? Consider the use of a temporary filler to deal with any lines remain after the use of botulinum toxin type A. Peels can also be used to soften any remaining deeper lines.

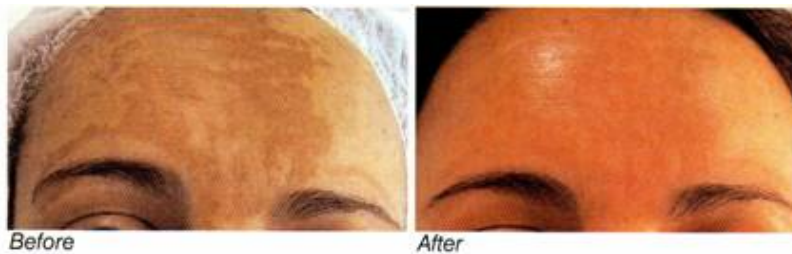Patient 1

Glabellar area pre and 3 weeks post Amelan Whitening peel and 8U VISTABEL' (BOTOX)



Patient 2

Forehead area pre and 3 weeks post Amelan Whitening peel and 24U VISTABEL'(BOTOX).



Periorbital area

There are three key questions to ask when considering lines in the periorbital area:

- Are the lines dynamic? Consider Botulinum toxin type A at an appropriate dose. Assess the position of the lines and choose injection sites accordingly.
- Are there lines at rest? Consider superficial laser skin resurfacing and botulinum toxin type A
- Is there "excessive tissue" that would benefit from surgery? Consider the impact of a blepharoplasty prior to the skin resurfacing and botulinum toxin type A.

Whilst botulinum toxin can be used alone to create a subtle, transient lateral brow lift, surgery is required in more severe cases of brow ptosis. Pre and post operative relaxation of the brow depressors with botulinum toxin provides better stability in the early months after surgery when the brow skin is adjusting to its new position.

With blepharoplasty, relaxation of the local muscles can allow for more accurate resection of skin and better placement of the incision during the surgical procedure.

PLANNING TREATMENT

All cosmetic procedures require a careful assessment of each patient's anatomical and personal characteristics when their face is relaxed and when they are smiling, concentrating, laughing and frowning. It is also important to discuss patients' hopes and expectations for the planned procedures, and to ensure that these are realistic that the patient has been informed of the potential risks.

In addition to taking a full history, the initial assessment is a useful time to:

- Discuss and establish what procedures are appropriate for the patient;
- Draw up a treatment plan, so that patients understand when procedures will be carried out, and in what order;
- Take pre-treatment photographs;
- Provide patients with information about pre- and post-procedure care.

ORDER AND TIMING OF TREATMENTS

Botulinum toxin and fillers

We advise patients to have botulinum toxin injections first and recommend waiting about one to two weeks before using fillers in the same area. In the glabellar area the results may be so good that most of the patients do not need a filler treatment. Patients need to understand that the maximal effect with botulinum toxin typically occurs most often by 14 days (maximum 20) and decisions on adjunctive fillers should be taken after this time.

For patients who insist on having the combination at the same treatment session, we advise injection of botulinum toxin followed by the appropriate filler.

Botulinum toxin, lasers and remodelling procedures

For laser resurfacing, we recommend treatment with botulinum toxin two weeks prior to laser treatment to smooth the skin, to obtain better resurfacing results. When the procedure is less invasive as with collagen remodelling techniques (lasers, IPL, RF) it is prudent to inject botulinum toxin a few days prior to or post therapy to avoid accidentally increasing diffusion resulting from either the thermal injury or mechanical pressure of certain hand pieces.

Botulinum toxin and IPL

Treatment regimes vary, but we have found in our personal practice that a series of five sessions, with three weeks between each session, gives optimal results. At one of the first two sessions botulinum toxin can be injected after the IPL treatment, and at the remaining sessions, IPL treatment is given on its own.

Botulinum toxin and peels

It is preferable that these treatments are not carried out at the same session with at least a week separating the treatments in order to decrease the risks of diffusion. If it is essential that they are combined, we advise that botulinum toxin injections are carried out following the peel. However, there are risks of increased diffusion particularly where there is substantial inflammation. Botulinum toxin A may be injected immediately after micro-epidermabrasion as there is no inflammation to modify diffusion.

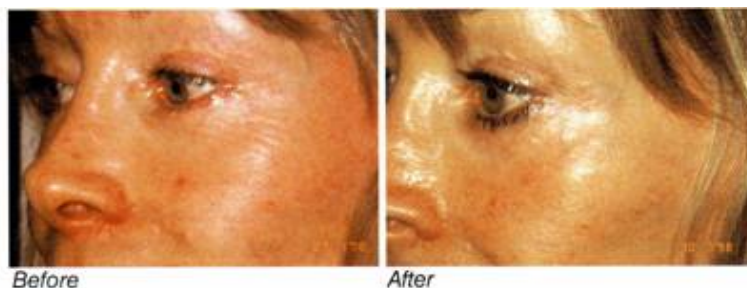
Botulinum toxin and facial surgery

Many patients ask for botulinum treatment to be carried out at the same time as their facial surgery, so that they can see the full effect as soon as possible. However, we try to convince them to have the treatments done separately, preferably with botulinum treatment being carried out shortly after surgery, when the face has started to heal and swelling has subsided.

This is because recent botulinum treatment may complicate the pre-surgical assessment by making it harder to see what is required. We prefer to wait for about three months after botulinum treatment before carrying out facial surgery.

Patient 3

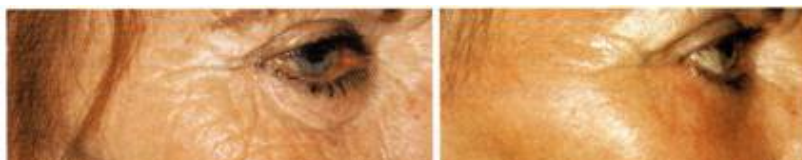Pre and 6 months post 3 treatments – Non-ablative laser remodeling (Aramis) + VISTABEL™ (BOTOX®) - photos courtesy of Dr. Ph. Levy.

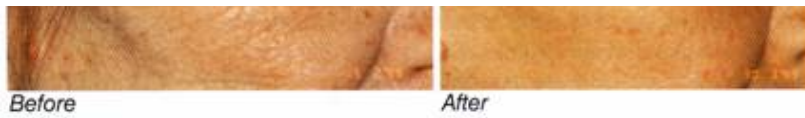

Patient 4

Pre treatment and 6 weeks post treatment - full face laser resurfacing (CO2), Erbium -YAG and VISTABEL™ (BOTOX®)

– photos courtesy of Dr. Ph. Levy.





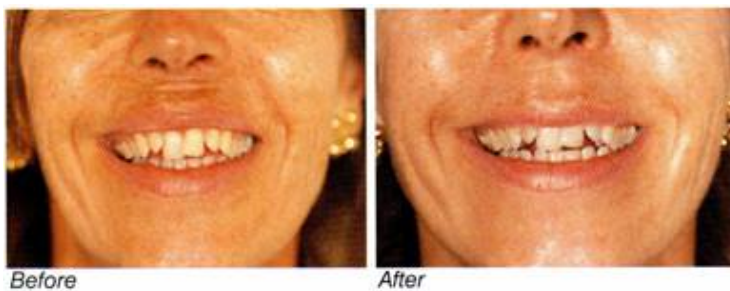Mid face area

In the central facial area, the major considerations are the nasolabial lines and structure of the cheek area and skin "condition". The decision making process here is based around severity of the lines and atrophy or scarring with a view to augmentation by filling.

For nasolabial lines, potential treatments can be chosen from a range of suitable fillers or fat injections dependent on the severity of the lines, potentially augmented with small accurately placed doses of botulinum toxin type A. Similarly for atrophic areas or acne scarring, fillers combined with laser skin resurfacing are preferred options.

Patient 5

Effect of VISTABEL' (BOTOX') (pre and 1 month post treatment) on the Elevator labiali muscles (2U/side total 4U) on wrinkles under the nose in the nasolabial area



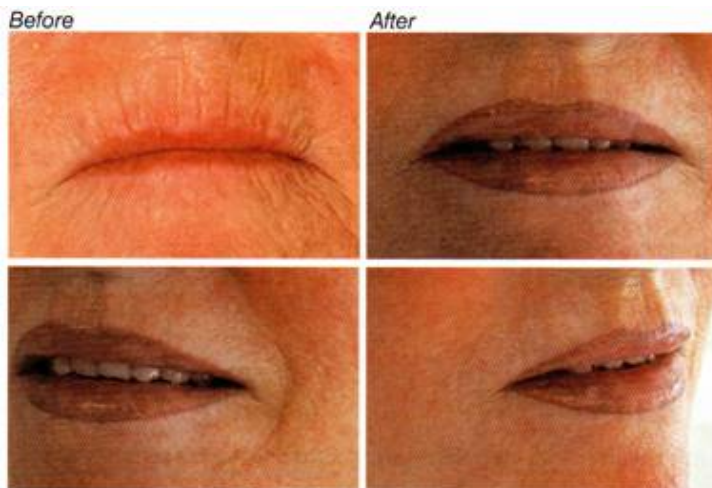
Perioral region

There are choices to be made in this area for the experienced practitioner, one of the main considerations is take time to build up the treatments for maximal effect. The key questions are:

- Are the wrinkles dynamic? Consider very small doses of botulinum toxin type A;
- Are the lips very thin and showing signs of atrophy? This is the main indication for the use of a good dermal filler designed for this purpose;
- Is there a combination of dynamic wrinkles and atrophy? Use small doses of botulinum toxin type A with filler to address both problems. If the wrinkles are deep consider laser resurfacing.

Patient 6

Pre and 2 months post treatment - Erbium: YAG laser resurfacing, VISTABEL'(BOTOX') total 4U (4x1U), hyaluronic acid filler and permanent make-up.



CONCLUSIONS

Combining botulinum toxin treatment with other cosmetic procedures can have significant advantages for patients and physicians. Combination treatment can give better, more long lasting results and, in some cases, even improve healing.

Initially, a combination of two or three procedures may be appropriate, with the beneficial effects subsequently being maintained with once or twice yearly botulinum toxin injections, and other repeat procedures as required.

By performing procedures in an optimal sequence, physicians can ensure that patients achieve the best possible results, with minimal adverse events.

The above is not intended as an instruction manual on introducing new treatments to your practice, but more an overview of suggestions on how to improve treatment results by effectively combining botulinum toxin with common, non-invasive aesthetic procedures.

FREQUENTLY ASKED QUESTIONS

1. Should I give botulinum toxin treatment to patients who have carried out peels or other treatment at home?

We prefer not to administer botulinum toxin to patients who have had recent treatments at home or at other clinics. It is essential to find out as much as possible about what patients have had done, and when. Depending on the answers to these questions, a safe, effective programme of treatment can be planned.

2. Can botulinum toxin be administered with retinoid creams?

We prefer not to mix botulinum toxin treatment with the early use of retinoid creams as it is easier to see the results of each individual treatment when administered separately. We would advise waiting for the patient to settle into their use of retinoids before treating them with botulinum toxin, and two months after botulinum treatment before starting a course of retinoids. However, many physicians see excellent results from combining the use of botulinum toxin treatment and retinoid creams early in treatment.

3. What precautions do you advise the patients to take when they have just had botulinum treatment?

The most important time is the first few hours after treatment. Patients must be reminded not to rub their face for two to three hours after treatment. (Editor's note: When treating the glabellar and/or forehead regions, in order to avoid risking upper eyelid ptosis by increased diffusion, I am much more conservative and I give my patients a detailed list of activities prohibited for 24 hours.)

4. Is there a risk of interactions between botulinum toxin and any of the chemicals used in peels or anaesthetic creams used prior to other procedures?

A skilful practitioner will ensure that the timings of treatments are appropriate so that no interactions may occur. This is why a schedule of treatments should be carefully explained and the rationale for a step-by-step treatment programme that will result in subtle changes and a natural look.

5. Can any of these procedures be combined with topical treatments that can be bought over the counter e.g. "cosmeceuticals"?

A. Care should always be taken with any concomitant treatment or medications with a full medical and complementary treatment history being taken. Patients should be advised to consider the use of sunscreens as routine adjunctive treatment to help prevent further skin damage.

References

1. de Maio M. Botulinum toxin in association with other rejuvenation methods. *J Cosmet Laser Ther* 2003; 210-212
2. Carruthers J, Carruthers A. A prospective, randomized, parallel group study analyzing the effect of BTX-A (Botox) and nonanimal sourced hyaluronic acid (NASHA, Restylane) alone in severe glabellar rhytides in adult female subjects: treatment of severe glabellar rhytides with a hyaluronic acid derivative compared with the derivative and BTX-A. *Dermatol Surg* 2003; 29: 802-809
3. Patel MP, Talmor M, Nolan WB. Botox and collagen for glabellar furrow. *Ann Plast Surg* 2004; 52: 442-446
4. Zimble MS, Nassif PS. Adjunctive applications for botulinum toxin in facial aesthetic surgery. *Facial Plast Surg Clin North Am* 2003; 11: 477-482
5. Carruthers J, Carruthers A. The effect of full-face broadband light treatments alone and in combination with botulinum toxin. *J Cosmet Laser Ther* 2004; 20: 255-266

bilateral crow's feet botulinum toxin type A chemodenervation. *Dermatol Surg* 2004; 30: 355-366
6. Matarasso S. Indications for skin resurfacing. *Skin resurfacing*. Coleman W, Lawrence N. Williams & Wilkins Ed. 1998; 2: 7-15

Further reading

Botulinum toxin in aesthetic medicine by Boris Sommer, Gerhard Sattler (eds). Blackwell Science, 2001. ISBN 0-632-06375-0.

El arte de rejuvenecer. El Botox, nuestro aliado by Dr Rafael Serena. Amat Editorial, 2004. ISBN 84-9735-8-8. Jean and Alastair Carruthers. *Using Botulinum Toxins Cosmetically*. 2003. Martin Dunitz, UK. ISBN 1-84184-217-6.

Nicholas J. Lowe (Editor). *Textbook of Facial Rejuvenation The Art of Minimally Invasive Combination Therapy*. 2002. Martin Dunitz, UK. ISBN 1-84184-095-5.
