



ORIGINAL ARTICLE

Reconstruction of Oral Cavity Defects With FMM (Facial Artery Musculomucosal) Flaps. Our Experience[☆]



Anna Sumarroca,^{a,*} Elena Rodríguez-Bauzá,^b Carmen Vega,^b Manuel Fernández,^b Jaime Masià,^b Miquel Quer,^a Xavier León^a

^a Servicio de Otorrinolaringología, Hospital de la Santa Creu i Sant Pau, Barcelona, Spain

^b Servicio de Cirugía Plástica, Estética y Reparadora, Hospital de la Santa Creu i Sant Pau, Barcelona, Spain

Received 5 August 2014; accepted 3 October 2014

KEYWORDS

Facial artery musculomucosal flap;
FMM flap;
Oral neoplasia;
Reconstruction;
Oral cavity;
Osteoradionecrosis

Abstract

Introduction and objectives: The facial artery musculomucosal (FMM) flap is a good option for covering small and medium-sized defects in the oral cavity because of its similar tissue characteristics and easy implementation.

Methods: We reviewed our results using this flap between 2006 and 2014. A total of 20 patients were included and 25 FMM flaps were performed, 16 right (64%) and 9 left (36%) flaps. Five patients had simultaneous bilateral reconstructions. The indications for flap surgery were reconstruction after resection of tumours in the floor of the mouth (8 cases, 40%), tumours in other sites of the oral cavity (4 cases, 20%), mandibular osteoradionecrosis (4 cases, 20%), oroantral fistula (3 cases, 15%), and postoperative ankyloglossia (one case, 5%).

Results: Reconstruction was successful in 92% of cases (n=23). Total flap necrosis occurred in one case and dehiscence with exposure of bone in another. Oral function and ingestion were satisfactory in all patients.

Conclusions: The facial artery musculomucosal flap is reliable and versatile for reconstruction of small and medium-sized intraoral defects. It allows functional reconstruction of the oral cavity with a low risk of complications.

© 2014 Elsevier España, S.L.U. and Sociedad Española de Otorrinolaringología y Patología Cérvico-Facial. All rights reserved.

[☆] Please cite this article as: Sumarroca A, Rodríguez-Bauzá E, Vega C, Fernández M, Masià J, Quer M, et al. Reconstrucción de defectos de cavidad oral con colgajos tipo FMM (colgajo músculo-mucoso de arteria facial). Nuestra experiencia. Acta Otorrinolaringol Esp. 2015;66:275–280.

* Corresponding author.

E-mail address: annasumarroca@gmail.com (A. Sumarroca).

PALABRAS CLAVE

Colgajo
músculo-mucoso de
arteria facial;
Colgajo FMM;
Neoplasia oral;
Reconstrucción;
Cavidad oral;
Osteorradionecrosis

Reconstrucción de defectos de cavidad oral con colgajos tipo FMM (colgajo músculo-mucoso de arteria facial). Nuestra experiencia**Resumen**

Introducción y objetivos: El colgajo músculo-mucoso de arteria facial (FMM) es un buen recurso para la cobertura de defectos intraorales de pequeño y mediano tamaño debido a sus características tisulares y a su facilidad de realización.

Métodos: Revisión retrospectiva de los resultados obtenidos con el colgajo, realizados en nuestro centro durante el periodo 2006–2014. Se intervino a un total de 20 pacientes sobre los que se realizaron 25 colgajos tipo FMM, 16 derechos (64%) y 9 izquierdos (36%). El colgajo se utilizó de forma bilateral y simultánea en 5 pacientes. Las indicaciones para la realización de los colgajos fueron: reconstrucción tras exéresis de neoplasias del suelo de la boca (8 casos; 40%), neoplasias en otras localizaciones de cavidad oral (4 casos; 20%), osteorradionecrosis mandibular (4 casos; 20%), fistula oroantral (3 casos; 15%) y anquiloglosia posquirúrgica (un caso; 5%).

Resultados: El colgajo consiguió una reconstrucción satisfactoria en el 92% de los casos (n=23). Se produjo una necrosis del colgajo en una ocasión, y una dehiscencia con exposición de hueso subyacente en otra ocasión. Se consiguió una ingesta y función oral satisfactoria en la totalidad de los pacientes.

Conclusiones: Dada su fiabilidad y versatilidad, el colgajo músculo-mucoso de arteria facial es una técnica adecuada para la reconstrucción de defectos orales de pequeño y mediano tamaño. Permite una reconstrucción funcional adecuada de la cavidad oral con escaso riesgo de complicaciones.

© 2014 Elsevier España, S.L.U. and Sociedad Española de Otorrinolaringología y Patología Cérvico-Facial. Todos los derechos reservados.

Introduction

To obtain adequate functionality, defect reconstruction at the level of the oral cavity requires special attention. There are a wide variety of reconstructive options depending on the defect nature and size, including grafts, local flaps, and free flaps. Small and medium defects can be successfully reconstructed with pedicle flaps, with low morbidity of the donor area. Over the last decades, pedicle flaps such as the submental,¹ supraclavicular,² or buccinator³ flaps have been used.

The facial artery musculomucosal (FMM) flap, initially described by Pribaz et al.,⁴ is a good resource for covering small and medium intraoral defects due to its tissue characteristics and its ease of performance.^{5,6}

The objective of our study was to review the indications, complications and functional results of reconstructing small and medium intraoral defects using the FMM flap.

Materials and Methods

We performed a retrospective review of the results obtained with type FMM flaps carried out in our centre during the 2006–2014 period. Patient characteristics, indications for flap use and results obtained were analysed.

The data were gathered from the clinical history notes made by the physicians in charge. The data collected was related to surgical technique (laterality and pedicle of the flap, surgical indication and type of defect to reconstruct),

flap viability, postoperative complications related to the procedure and functional result achieved with the reconstruction, including tongue mobility, articulation (degree of buccal opening) and swallowing. Follow-up time was measured from surgery date until the date of last contact or of patient death. Average follow-up period for the patients included in the study was 3.2 years.

Patient Characteristics

During the study period, 20 patients in all were operated, on which 25 FMM type flaps were performed, 16 right (64%) and 9 left (36%). In 5 patients bilateral simultaneous flaps were used for the reconstruction. Mean patient age was 59 years (range 28–77 years). The flap was used with male patients on 14 occasions (70%) and with females on 6 occasions (30%). Of the 20 patients, 14 (70%) were smokers or ex-smokers.

Table 1 shows the distribution of the indications for flap performance. Most of the flaps (n=17; 68%) were used in the reconstruction step after excision of a tumour in the oral cavity or oropharynx.

Tumour histopathology corresponded to squamous cell cancer in all cases. Tumour extension was classified as stage T1N0 in 8 cases, T2N0 in 2 cases, T2N1 in 1 case, and T4N0 in 1 case. Cervical dissection was performed simultaneously in 6 patients. When area I was dissected, the facial artery could be preserved on 6 occasions. No cervical dissections were performed in 6 oncological patients. All cases were superficial T1N0 tumours, in which the Oncological Committee at

Table 1 Indications for Reconstruction With FAMM Flaps.

Surgical indication	Number of patients (%)
Neoplasia of the floor of the mouth	8 (40)
Neoplasia in sites other than the oral cavity	4 (20)
Mandibular osteoradionecrosis	4 (20)
Oroantral fistula	3 (15)
Postoperative ankyloglossia	1 (5)
Total	20 (100)

our centre considered maintaining clinical monitoring of the ganglion areas sufficient. Until this study was carried out, none of the patients in our series showed tumour recurrence at local or regional levels. Five of the patients received adjuvant treatment with radiation therapy.

On 8 occasions, the FAMM flap was indicated in the treatment of patients with osteoradionecrosis, oroantral fistula or postoperative ankyloglossia.

Surgical Technique

The FAMM flap was designed with an inferior pedicle (anterograde flow) 20 times (80%) and with a superior pedicle (retrograde flow) 5 times (20%). The facial artery trajectory was located using Doppler and the myomucosal flap was designed over its pathway. When designing the flap, the location of the Stenson's duct papilla was taken into consideration in all cases, tracing the posterior flap border in front of it. A few transfixion silk stitches were inserted at lip corner and cheek levels as separators. Next, the flap margins were infiltrated with local anaesthesia and adrenalin to facilitate dissection. The approach was started at the level of the buccal corner, 1 cm behind the labial fold. Deep dissection was performed, affecting the mucosa, submucosa, and buccinator muscle until the facial artery was identified. Once this artery was exposed, the anterior flap border was handled, adapting it to the facial artery trajectory, which is normally very sinuous. The flap was then dissected, including the mucosa and submucosa, the section underlying the buccinator muscle and the facial artery. To avoid the risk of shearing and detaching the facial artery and to make it easier to elevate the flap safely, a few sutures (4/0 Vicryl) were inserted between the mucosa border and the muscle. Flap length was calculated in proportion to the defect, testing the theoretical point of rotation. The facial artery was then ligated and sectioned in the distal border of the flap. The posterior border of the flap was dissected from this point. The venous flap drainage depended on the submucosal plexus, so it was not necessary to include the facial vein in the flap. However, the precaution should be taken of including a reasonable part of the periarterial areolar tissue to ensure this point. Following its elevation, the flap is transposed to the defect to reconstruct. It is important to carry out this movement without tension. Otherwise it is essential to increase the pedicle dissection at the level of the flap base (Fig. 1). Once the flap has been adapted to the intraoral defect, it is sutured using interrupted stitches of absorbable material (3/0 Vicryl).

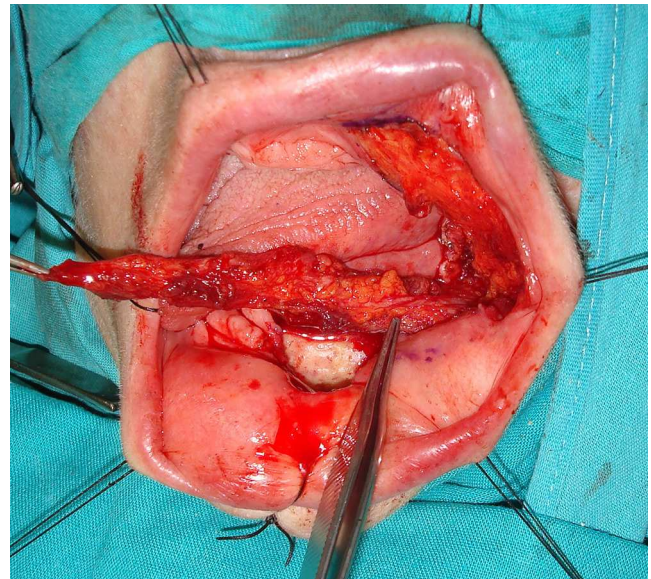


Figure 1 Design and dissection of a FAMM flap for reconstructing the defect in the floor of the mouth, after tumour excision.

In dentate patients, a space maintainer with dental block was placed in the first postoperative days.

Results

Flap Viability

Our results show that the FAMM flaps had complete viability in 92% of the occasions (n=23). There was 1 case of total flap necrosis, corresponding to a female patient with history of oropharynx carcinoma treated with radiation therapy, in which the flap was indicated for treating osteoradionecrosis. During that patient's operation, despite the lack of surgical antecedents over the cervical area that would justify obliteration of the facial artery, it was impossible to identify this artery. Consequently, a pedicle flap was fashioned over the area of the theoretical pathway of the facial artery, suturing it over the defect left at mandibular level after curettage of the focus of bone necrosis. At 48 h postoperative, complete flap necrosis required its removal.

In an additional case corresponding to a patient with a T1N0 stage cancer of the floor of the mouth, there was a necrosis of less than 1 cm of the distal section of the flap. This was debrided and closed in secondary intention, without affecting the reconstructive goal.

Complications

Besides the 2 cases in which flap viability was partially or completely compromised, 3 patients had some type of complication related to the procedure. There was 1 patient with osteoradionecrosis in which the FAMM flap was used in reconstructing a mucous defect after bone curettage, in which dehiscence occurred in the suture between the flap and the defect, with exposure of the underlying bone. In another case, in which the flap was used to repair an oroantral fistula, a dehiscence also occurred in the flap

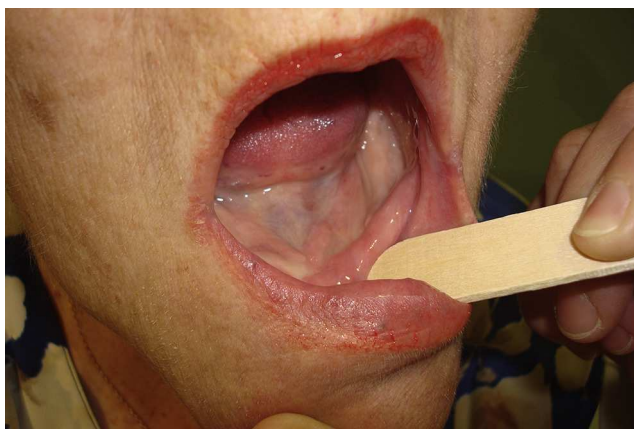

Figure 2 Flap result in the patient shown in Fig. 1, at 5 months postoperative.

suture over the bone defect, with reappearance of the fistula. Lastly, a distal branch of the buccal branch of the facial nerve was injured in 1 patient during a particularly difficult dissection. This patient presented buccal corner asymmetry that did not improve over time.

The FAMM flap fulfilled its reconstructive goal in 85% (17/20) of the patients that underwent surgery (Fig. 2). It bears emphasizing that, in patients for whom the FAMM flap was used after excision of an oral cavity tumour, the reconstructive objective was achieved 100% of the time (12/12 patients, 17/17 FAMM). However, using the flap resolved the reconstructive problem in only 62% of the cases in which the indication was not tumour excision (5/8 patients, 5/8 FAMM).

None of the FAMM procedure carried out required urgent revision surgery. On 3 occasions, the pedicle was made independent in a second surgical step to facilitate dental rehabilitation. Five patients presented retractable adhesions in the donor area, which required Z-plasties in the mucosa scar in an interval from 3 months to 2 years after the surgery.

One patient with important pathological antecedents (a heart transplant among them) suffered complications not directly related to the surgical procedure in the immediate postoperative period, with later respirator failure, ICU admission, tracheotomy and death at 30 days after the intervention from respiratory complications. There were no salient complications in the postoperative evolution of the rest of the patients. The periods of hospital stay corresponding to the patients treated with FAMM flaps ranged from 2 to 30 days (median of 6 days).

Functional Results

We did not have a dental registry available for the patients included in the study. Consequently, we could not establish the type of patient-tolerated diet after the surgery. Buccal aperture was evaluated based on the subjective opinion of the patient and the surgeon in charge. Two patients presented slight trismus, which did not prevent oral feeding. No notable deficiencies in the capability of word articulation were seen in any of the patients assessed.

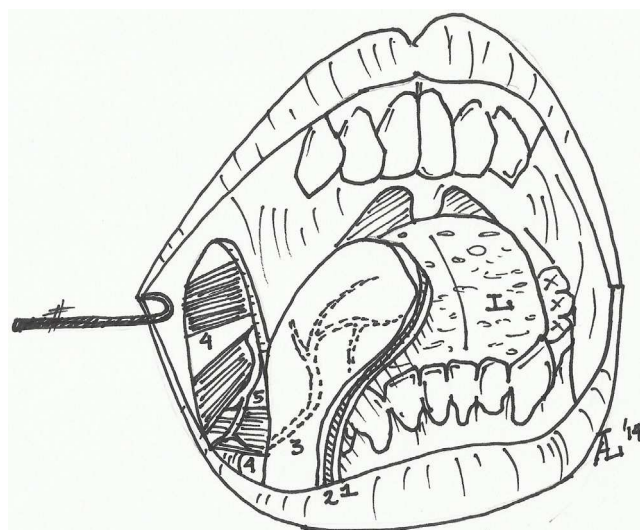


Figure 3 Anatomical concept of the FAMM flap. 1: mucosa and submucosa; 2: buccinator muscle; 3: facial artery branches; 4: facial musculature; 5: facial nerve branches; L: tongue. Source: A. Leidinger.

From the case histories, it appears that satisfactory food intake, with a normal or bland texture depending on dentition, was achieved by all the patients. Osseointegrated implants were placed in 1 toothless patient. Rehabilitation with dental prosthesis was achieved in another case. The rest of the patients without teeth rejected dental rehabilitation. It should be noted that dental rehabilitation is not included in the services of the Spanish public health care system.

Discussion

The FAMM flap is an axial flap composed of mucosa and submucosa from the intraoral cheek, part of the buccinator muscle and the deepest part of the labial orbicular muscle, including the facial artery (Fig. 3). It can be designed with an inferior pedicle with anterograde flow in the facial artery⁷ or with a superior pedicle with retrograde flow. Defect location determines the use of one or the other pedicle. If the use of a flap with anterior flow is associated with a cervical ganglion dissection because of a tumour, it is important to respect the integrity of the facial artery at that level. The flap has a wide arch of rotation due to its axiarity. It is not essential to include the facial vein in the flap (this artery is rarely incorporated into the flap), given that venous drainage is also carried out through the buccal venous plexus located in the submucosa.⁸

Using FAMM flaps makes it possible to excise a tumour and perform the reconstruction in the same operation, adapting the flap to the defect thanks to its great versatility.⁶ It is likewise indicated for reconstructing mucous defects such as those associated with radionecrotic ulcers, oroantral fistulae or palatine fissures.⁹⁻¹¹

Ayad and Xie⁸ have recently carried out a systematic review of the indications and results obtained with FAMM type flaps based on data published in various series. The authors reviewed 38 studies, which included information on

Table 2 Inherent Advantages and Disadvantages of Using FAMM Flaps in the Oral Cavity and Oropharynx.**Advantages**

Good viability
 Facial artery easily identified
 Surgery with low intra- or postoperative mortality
 Use of mucosa to replace mucosa excision
 Possibility of excising and reconstructing in a single surgical operation
 Wide arch of rotation
 Possibility of superior or inferior pivoting, depending on the defect
 Good aesthetic result, without external incision
 Possibility of dental rehabilitation
 Performable in patients after chemotherapy and radiation therapy
 Easy flap refinement if there is excess tissue

Disadvantages

Need to preserve the facial artery if there is cervical dissection
 Need for exodontia or bite blocker in dentate patients because of the risk of pedicle compression
 Limited maximum width (2.5–3 cm)
 Need for a 2nd operation to make the pedicle independent
 Need for Z-plasties in a second surgery if there is retraction of cheeks or retractable adhesions

485 flaps, a majority (65%) of inferior pedicle. The main indications for the flaps in the various series included reconstruction following tumour excision in the oral cavity or oropharynx (70.7%), closure of perforations or fistulas at oral cavity or nasal level (12.7%), and osteoradionecrosis (6.5%). These data coincide in great measure with the indications for which the treatments were performed in our centre.

In contrast to the tunnelled nasolabial flap, one of the advantages of the FAMM flap is that there are no or minimal aesthetic sequelae, because there are no external scars.¹² Facial nerve branches are located more superficially than the facial artery and they generally are not included in the plane of dissection, which prevents their injury. Another advantage with respect to cutaneous flaps is that, as the FAMM is a mucosal flap, it allows reconstruction with a tissue histologically similar to the original tissue. This ensures, in most situations, better functional results (tissue like tissue). It is also a flap that keeps its reliability in patients that have received prior radiation therapy.

One of the limitations of the flap is that the maximum width obtainable is some 2.5–3 cm to allow primary closure of the donor area. Another limitation is that, in planning the surgery, there is a need to place a dental block piece in the immediate postoperative period to prevent patients with teeth from biting the pedicle. In addition, flap volume or pedicle presence can cause patient discomfort, requiring a new surgical intervention to remodel the flap or make the pedicle independent. [Table 2](#) summarises the inherent advantages and disadvantages of using FAMM flaps in oral cavity and oropharynx.

Using this flap in the repair of skull base and sphenoid plane defects is being investigated.¹³

Conclusion

Because of its reliability and versatility, the FAMM flap is appropriate for reconstructing small and medium oral defects. The flap presents few complications and ensures adequate functional reconstruction of the oral cavity.

Ethical disclosures

Protection of human and animal subjects. The authors declare that no experiments were performed on humans or animals for this investigation.

Confidentiality of Data. The authors declare that they have followed the protocols of their work centre on the publication of patient data and that all the patients included in the study have received sufficient information and have given their informed consent in writing to participate in that study.

Right to privacy and informed consent. The authors declare that no patient data appears in this article.

Conflict of Interests

The authors have no conflicts of interest to declare.

References

1. Amin AA, Sakkary MA, Khalil AA, Rifaat MA, Zayed SB. The submental flap for oral cavity reconstruction: extended indications and technical refinements. *Head Neck Oncol.* 2011;3:51.
2. Chiu ES, Liu PH, Friedlander PL. Supraclavicular artery island flap for head and neck oncologic reconstruction: indications, complications, and outcomes. *Plast Reconstr Surg.* 2009;124:115–23.
3. Bozola AR, Gasques JA, Carriquiry CE, Cardoso de Oliveira M. The buccinator musculomucosal flap: anatomic study and clinical application. *Plast Reconstr Surg.* 1989;84:250–7.
4. Pribaz J, Stephens W, Crespo L, Gifford G. A new intraoral flap: facial artery musculomucosal (FAMM) flap. *Plast Reconstr Surg.* 1992;90:421–9.
5. Joshi A, Rajendraprasad JS, Shetty K. Reconstruction of intraoral defects using facial artery musculomucosal flap. *Br J Plast Surg.* 2005;58:1061–6.
6. Ayad T, Kolb F, de Monés E, Mamelle G, Temam S. Reconstruction of floor of mouth defects by the facial artery musculomucosal flap following cancer ablation. *Head Neck.* 2008;30:437–45.
7. Dupoirieux L1, Plane L, Gard C, Penneau M. Anatomical basis and results of the facial artery musculomucosal flap for oral reconstruction. *Br J Oral Maxillofac Surg.* 1999;37:25–8.
8. Ayad T, Xie L. Facial artery musculomucosal flap in head and neck reconstruction: a systematic review. *Head Neck.* 2014 [Epub ahead of print].
9. Ashtiani AK, Emami SA, Rasti M. Closure of complicated palatal fistula with facial artery musculomucosal flap. *Plast Reconstr Surg.* 2005;116:381–6 [discussion 387–8].
10. Dolderer JH, Hussey AJ, Morrison WA. Extension of the facial artery musculomucosal flap to reconstruct a defect of the soft palate. *J Plast Surg Hand Surg.* 2011;45:208–11.
11. Hatoko M, Kuwahara M, Tanaka A, Yurugi S. Use of facial artery musculomucosal flap for closure of soft tissue defects of

- the mandibular vestibule. *Int J Oral Maxillofac Surg.* 2002;31: 210–1.
12. Hagan WE1, Walker LB. The nasolabial musculocutaneous flap: clinical and anatomical correlations. *Laryngoscope.* 1988;98:341–6.
 13. Xie L, Lavigne F, Rahal A, Moubayed SP, Ayad T. Facial artery musculomucosal flap for reconstruction of skull base defects: a cadaveric study. *Laryngoscope.* 2013;123:1854–61.