

**Aesth. Plast. Surg. 23:267-270, 1999**

Jorge Planas, M.D., and Beatriz B. Morais, M.D.  
Barcelona, Spain

**Abstract.** The appearance of the superficial liposuction technique has permitted the surgeon to advance in 1 indications for treating localized lipodystrophy, without skin resection. With the coetaneous retraction phenomenon that follows superficial liposuction, pendulous abdomen, which was once treated by classical dermolipectomies, can now be treated with liposuction alone, obtaining satisfactory results. The authors recommend this form of treatment for patients with pendulous abdomen and with good skin quality, with few or no stretch marks, and with little or no diastases of the rectoabdominal musculature.

**Key words:** Liposuction-Superficial liposuction-Coetaneous retraction-Pendulous abdomen.

### Introduction

Continuous advancement in plastic surgery techniques occasionally leads the surgeon to readjust his point of view when indicating one or another type of intervention. With the appearance of superficial liposuction at the end of the 1980s [2-4], each time it is more evident that the indication for large extractions of fat in the pendulous abdomen gives very satisfactory results. Thus we find that many of the abdominal lipectomies that we indicated only a short time ago can now be indicated as extensive liposuctions.

Thanks to the phenomenon of coetaneous retraction that follows the superficial liposuction, we can therefore increase our range of indications of liposuction without skin resection [2-5,7]. Liposuctions were previously restricted to abdomens with discrete lipodystrophies and with good skin quality. Only "deep" liposuction was used, which acted in the lamellar fat layer, located between the superficial fascia and the muscular fascia. Liposuction was not performed in the more superficial areolar fat layer, situated between the dermis and the superficial fascia, for fear of the appearance of skin surface irregularities [8,11,13]. With the evolution of the technique and the demonstration of the existence of such scar retraction that follows the liposuction of the areolar layer, the retraction of a great volume of fat without skin resection has been made possible. Coetaneous retraction is due to the reduction of the tension in the skin when the fatty volume distended it is removed, as is also possible due to stimulation of the miofibroblasts by the dermis trauma [1,6]. Large quantities of fat can be removed mainly in patients with elastic skin favoring the retraction. Under such conditions the patients present a very good response to the technique of associated "deep" and "superficial" liposuction.

### Surgical Technique

Eleven female patients were treated between 1993 and 1995, all having extensive lipodystrophy of the abdominal region and pendulous abdomen. The average age was 42 years, the youngest patient being 20 and the oldest 64. Ten of these patients (90.1%) presented associated lipodystrophies of the abdomen and flanks, while one (9.9%) presented abdominal lipodystrophy only. Furthermore, three of them (27.2%) also presented abdominal lipodystrophy of the back, two (18.1%) of the internal face of the thighs, and one (9.9%) of the trochanteric region. The associated lipodystrophies were mostly treated in subsequent interventions.

General anesthesia was used in 10 patients (90.1%) and epidural anesthesia 1 (9.9%). In all cases a solution of physiological saline with adrenaline at a concentration of 1:200,000 was used to infiltrate the areas to be suctioned. The quantity of solution infiltrated varied according to the extension of this area and the volume to be extracted, with an average of 1300 ml per patient. A 6-mm blunt cannula was used for liposuction of the lamellar layer and cannulas of 3 and 4 mm, also with blunt tips, were used for superficial liposuction. Because the lamellar fat layer consists of large lobules of fat loosely packaged in poorly delimited spaces, bound by oblique fibrous septa, the fat is easily suctioned with a 6-mm cannula. On the other hand, areolar-layer fat consists of small, well-defined lobules, firmly contained by more dense vertical fibrous septa, connected to the deepest dermic layer. This is better treated with the thinner 3- and 4-mm cannulas, which permit removal of

without damaging the fibrous septa, which are important elements of skin support [6].

Prophylactic antibiotics were given to all patients. Reston-like dressings and a compressive girdle were used. The Reston was removed after the first 24 h and the girdle was kept on for 30 days. All the patients checked into the clinic the night before the operation and could leave the very next day.

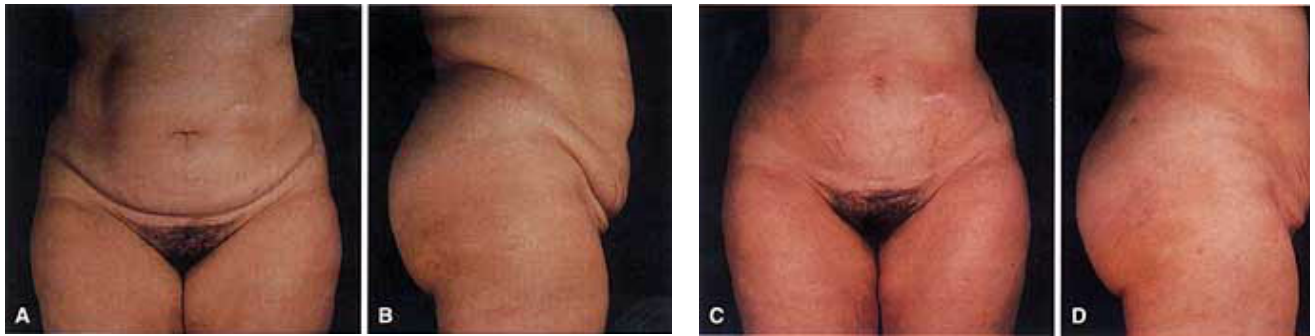


Fig. 1. A 32-year-old female patient with pendulous abdomen. (A,B) Preoperative appearance. (C, D) Postoperative view after 12 months

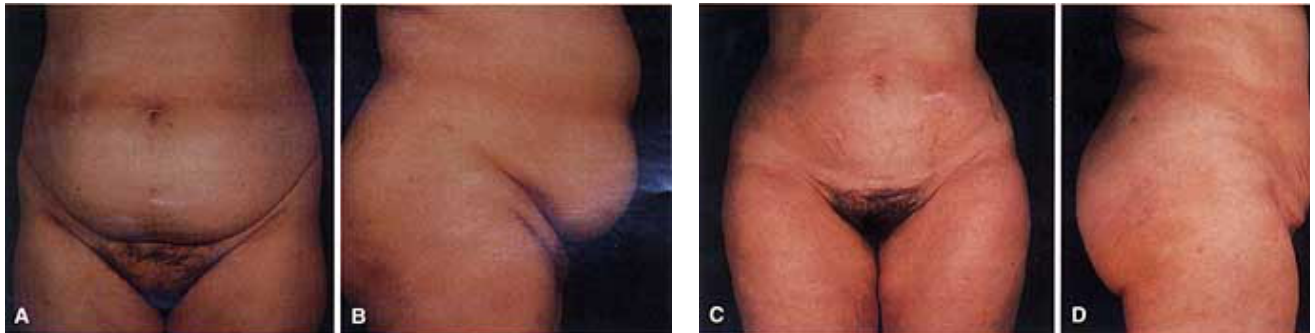


Fig. 2. A 53-year-old female patient with pendulous abdomen. (A, B) Preoperative view. (C, D) Postoperative appearance after 9 months.

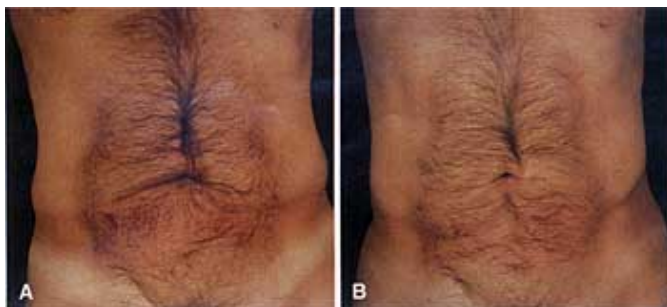

Fig. 3. A 50-year-old male patient. (A) Preoperative appearance. (B) Postoperative view after 4 months.

## Results

The total volume of fat removed from each patient was on average 2800 ml, with a minimum of 1900 ml and a maximum 5050 ml. From the abdomen the average extraction was 1680 ml, with a range of 700 to 3250 ml, and from the flanks the volume ranged from 200 to 1000 ml on each side (an average of 550 ml). Three of the patients needed blood transfusion previously programmed in the regimen of autotransfusion. The blood was collected 1 month before the intervention. Autotransfusion is always programmed whenever there is the intention to remove a volume greater than 3000 ml. The use of Reston dressings had the aim of reducing the formation of echimosis and hematomas, diminishing, in this way, the incidence of postoperative anemia. Furthermore, with the use of the Reston a more regular skin surface is obtained, since the dressing creates a better distribution of the fat cells displaced by the liposuction [8]. There were no complications and the patients were able to leave the clinic the day after surgery.

The aesthetic results that we have obtained in pendulous abdomens using this technique have been very satisfactory and in some cases even surprising (Figs. 1 and 2). The third case shows very clearly the phenomenon of skin retraction in the periumbilical region, where there was a great excess of skin before the operation (Fig. 3). This male patient did not present a pendulous abdomen so does not form part of the case history. His photographs are included to demonstrate the phenomenon of skin retraction.

## Conclusions

The authors would like to draw attention to the advantages of increasing the range of indications for liposuction in the treatment of localized abdominal lipodystrophies. Superficial liposuction is a technique that provides a perfect complement to "deep" liposuction, because, besides improving the results obtained, it enables the indication for liposuction in significantly more cases. The use of liposuction without skin resection brings evident advantages, such as the absence of large scars and a lower amount of postoperative complications such as infection, dehiscence, and seroma, which are more likely to occur in classic dermolipectomies. Other advantages include faster patient recovery, a shorter stay in the clinic, and a

return to work activities. More and more patients with advanced abdominal lipodystrophies can be treated using only liposuction, without skin resection. If patients show a good skin quality, they are more likely to obtain better results, since the surgeon will be sure of attaining the desired coetaneous retraction. The authors envisage a change in the approach to the indications for liposuction in selected patients with good skin quality.

---

## References