

## The Use of Integra<sup>TM</sup> in Rhinoplasty

Jorge Planas

Received: 1 March 2010 / Accepted: 8 June 2010 / Published online: 31 July 2010

© Springer Science+Business Media, LLC and International Society of Aesthetic Plastic Surgery 2010

**Abstract** Different biosynthesized materials and autologous grafts have been used for many years to increase the size or to change the shape of the nasal dorsum in augmentation rhinoplasty. To avoid the undesirable effects of these materials, such as reabsorption, intolerance, granulomas, visualization of the graft's edges, and the migration of the implant, a new technique is proposed that uses a dermic regeneration template (Integra<sup>TM</sup>). The authors have performed 56 surgeries for patients with different indications, and 30 of these patients have been followed up for a minimum of 12 months. The advantage of using this template, a sheet comprising a porous matrix of collagen fibers and glycosaminoglycans, is that it provides a structure for autologous dermic tissue regeneration. Its handling versatility once the silicone sheet is removed allows it to be folded over itself until the needed thickness is obtained as well as the desired aesthetic results. The authors believe that the dermic regeneration template (Integra<sup>TM</sup>) is a good alternative filler material because it is completely reabsorbed and replaced by autologous dermis. The action is not to replace but to help the development of the patient's own tissue, avoiding a possible intolerance because it does not act as a foreign body. The volume remains stable throughout time, and overcorrection is not necessary.

**Keywords** Augmentation rhinoplasty · Dermic regeneration template · Dorsum nasi · Integra<sup>TM</sup> · PGF

Many procedures to correct volume defects in rhinoplasty are described in the medical literature, such as osseous or

cartilaginous autologous grafts, lyophilized bone, and synthetic materials. However, all show some undesirable effects such as reabsorption, intolerance, granulomas, visualization of the graft's edges, and migration of the implant [1–6]. With the aim of trying to avoid these undesirable effects, we describe our protocol for the correction of dorsum nasi defects by using other techniques, especially the application of a dermic regeneration template (Integra<sup>TM</sup>, Integra Life Sciences Corporate, Plainsboro, NJ, USA).

When osseous dorsum nasi defects or the nasofrontal angle needs moderate augmentation, we use demineralized bone matrix activated with platelet growth factors (PGF). When it is necessary to correct more important defects of the osseous dorsum nasi that require a greater volume of correction or those that affect not only the osseous dorsum but also the cartilage, demineralized bone matrix with PGF is not the best option for two reasons: (1) It cannot obtain a large increase in volume, and (2) an osseous bed is needed to start the process of osseous regeneration. For these cases, we therefore prefer to use the dermic regeneration template sheet (Integra<sup>TM</sup>), which allows constant regeneration of autologous dermic tissue with suitable thickness [7, 8]. The template obtains excellent results, especially in posttraumatic cases and secondary rhinoplasties.

The dermic regeneration template is a porous matrix of glycosaminoglycans and collagen that provides a three-dimensional structure necessary for cellular invasion and growth. This functions to stimulate the organism to create autologous dermis. Although it is a synthetic material, the template is completely absorbed in 4–6 months [9] and replaced totally by the patient's own tissue. It is easy to handle and versatile because it can be folded on itself and because the size and shape of the implant can be designed as desired.

The proposed surgical treatment is an alternative to the use of other grafts to restore the defects of the dorsum nasi in

J. Planas (✉)

Clinica Planas, Pere de Montcada, 16, 08034 Barcelona, Spain  
e-mail: jorge@clinica-planas.com



augmentation rhinoplasty. It uses the dermic regeneration template as the material for increasing volume, improving contours, and hiding aesthetic defects. Thus, we aim to demonstrate that this material can be grafted under the cutaneous tegument without complications and that it achieves its objective much the same as the coating placed on damaged tissue in the case of burns or tissue lost [10–12].

Finally, if instead of volume, the need is for more thickness to the entire nasal contour (in cases of very thin skin to avoid show-through of the osteocartilaginous structure), we use either the dermis regeneration template (Integra™) or a cellular dermis (Alloderm™, Lifecell, Branchburg, NJ, USA) and cover all of the dorsum nasi with it.

## Materials and Methods

The use of the dermic regeneration template in plastic surgery has already succeeded as treatment for other areas of the body such as correction of cranial osseous defects [7]. Our experience using the dermic regeneration template (Integra™) as a solo technique or as a procedure in addition to rhinoplasty currently consists of 56 patients.

Informed consent for the use of Integra™ was obtained from all the patients after all other options of different materials had been explained. At this writing, the follow-up period for the first cases is 27 months. We have been able to assess the amount of regenerated tissue, durability, and absorption afterward. For 30 patients, the minimum follow-up period has been 12 months.

Of the 56 patients (47 women and 9 men), 55 have had surgery under general anesthesia, and only 1 had surgery

with local anesthesia. The surgeries consisted of 32 open and 24 closed rhinoplasties. The 56 cases included 2 posttraumatic, 18 secondary, and 36 primary rhinoplasties.

The complete dorsum nasi was increased in 41 cases, and a partial increase was experienced in 13 cases. In two cases, the area of the right upper lateral cartilage also was filled, and in one case, both upper lateral cartilages were filled.

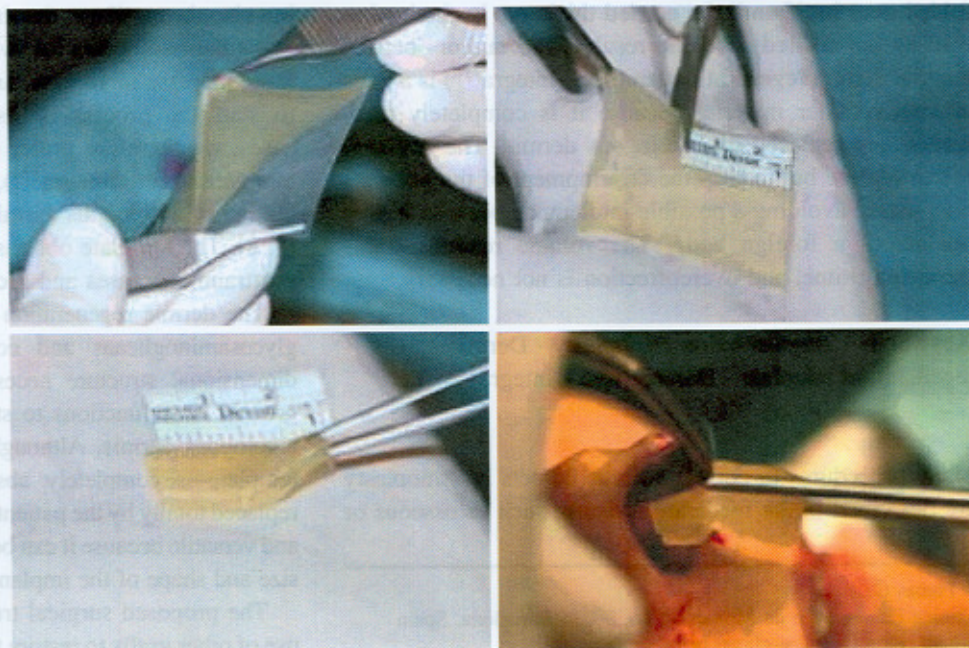
Only one layer of Integra™ was applied in most of the cases. We folded the sheet for 10 patients to obtain two layers. For five patients we folded the sheet more times to get three layers, and for one patient, we folded the sheet in four layers.

One sheet of a dermic regeneration template was used in all cases. Before application of the sheet, the superficial silicone layer was removed because this works as an epidermis when it is used as an injury cover. The layer size used was of 5 × 5 cm, and its design was handled according to the area to be filled.

We cut out the necessary amount of template considering that the material could be folded on itself as needed to obtain the desired result in each case. It is better to carry out the aforementioned design before removing the superficial coat of silicone because it makes trimming easier. Once designed, the material should be left to soak in saline solution for a few minutes before its placement. The silicone coat then is removed because its function is not necessary, and it could work as a foreign body (Fig. 1).

It is important to place the layer carefully so that it is well spread over all the area to be treated, avoiding folds and thus some possible contour irregularities later. The template placement can be performed as a unique technique, or it can

**Fig. 1** After removal of the silicone layer, the necessary amount can be designed and cut out, with the option of folding the material on itself as needed and then placing it in the area to be filled





be associated with a complete rhinoplasty. Depending on the maneuvers associated with the performed technique, a tampon will be placed, as well as a plastic splint, if necessary. None of the patients needed a secondary revision after augmentation with the dermic regeneration template.

## Results

The dermic regeneration template (Integra™) achieved very good results for patients with dorsum nasi defects such as saddle nose deformities, overresected dorsum, traumatic noses (Figs. 2, 5, and 6), and dorsum asymmetries (Figs. 3 and 4). It is mandatory to have a solid base on which to place the dermic regeneration template. For cases in which a solid base is absent, we prefer to use autologous osseous or cartilaginous grafts.

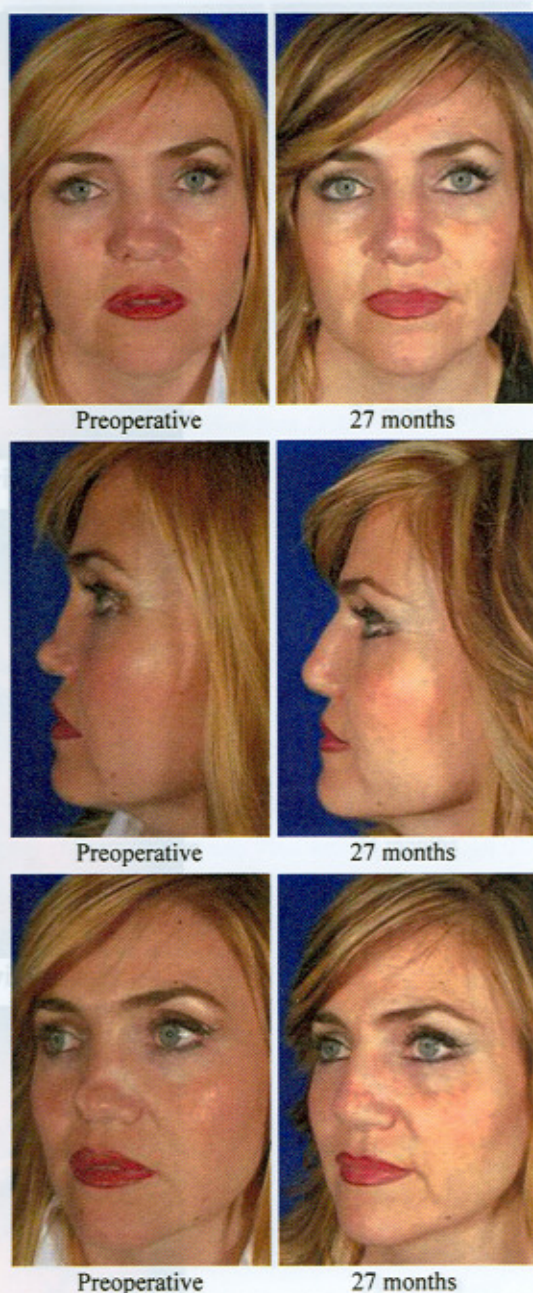The following sections introduce five of the most representative cases included in this study. These cases include examples of surgical indications from our experience using the dermic regeneration template (Integra™) in rhinoplasty.

### Case 1

A 40-year-old woman who experienced a contusion trauma in childhood had a bone fracture that caused a significant depression of the dorsum nasi. She also presented with altered respiratory function. Her physical examination showed a saddle nose deformity in the dorsum nasi as well as septal deviation toward the left. The surgical treatment consisted of an open rhinoseptoplasty, with turbinectomy and head resection of the right inferior concha, reconstruction with a columella strut, interdomal suture of both alar cartilages, lateral and medial osteotomies, placement of four layers of Integra™ folded on itself on the osteo-cartilaginous dorsum, and a 0.5 × 0.5-cm graft of auricular cartilage in the supratip break area to give more consistency to the aforementioned area (Fig. 2).

### Case 2

A 53-year-old woman had antecedents of a previous rhinoplasty with depression in the dorsum nasi. At her examination, an excess of resected osseocartilaginous dorsum was noted as well as a deviation of the dorsum nasi. The proposed corrective surgery, performed through a closed rhinoplasty, included rasping of the small monticulus in the osseous dorsum nasi, left unilateral osteotomy to correct deviation, resection of the excess lower lateral cartilage, and placement of Integra™ folded on itself in two sheets for all the extension of the dorsum nasi (Fig. 3).



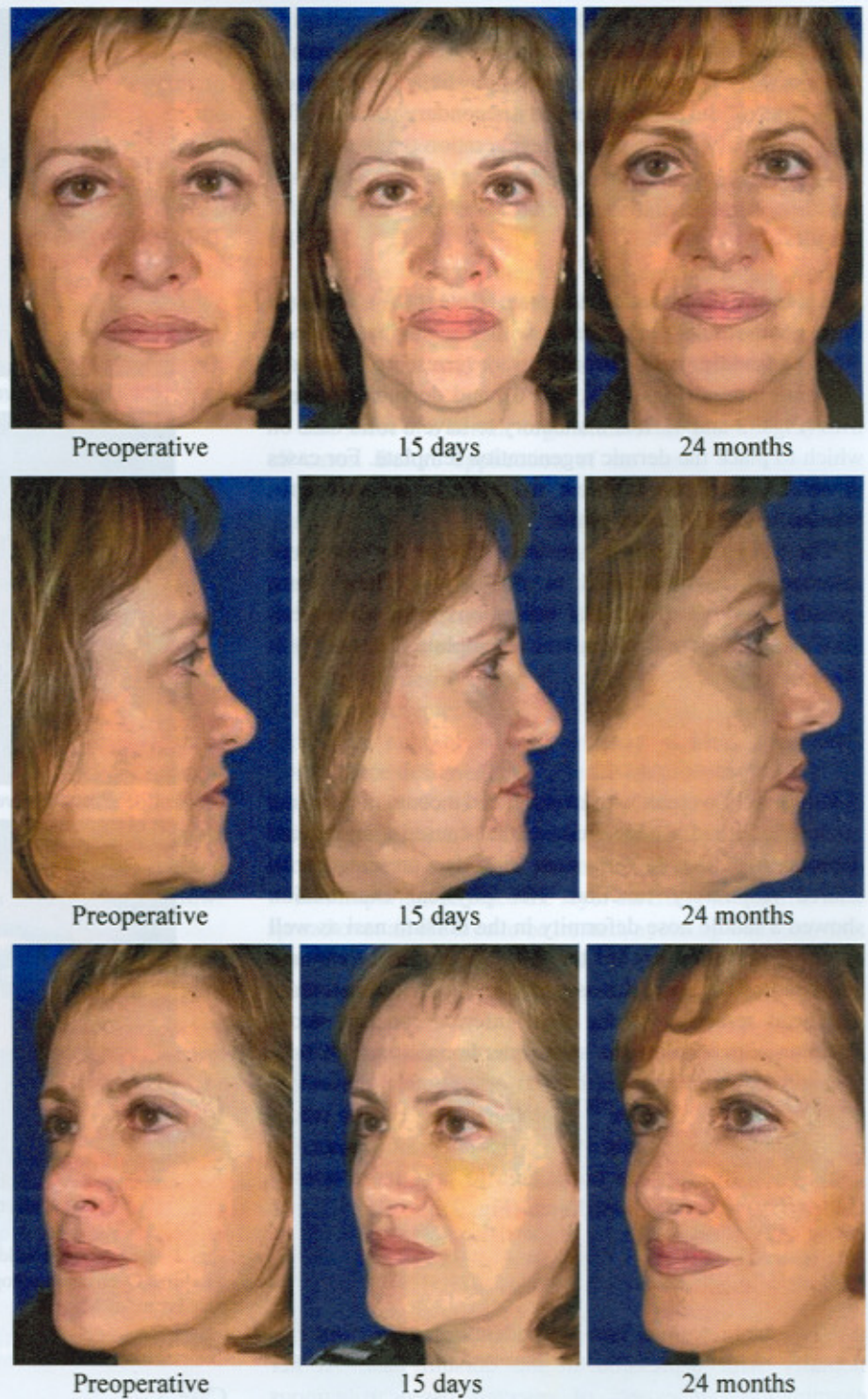
**Fig. 2** Patient with a saddle nose and a marked supratip break due to a trauma. Open rhinoseptoplasty was performed with the placement of four layers of Integra™

### Case 3

A 31-year-old woman with a history of rhinoplasty and no respiratory difficulty requested improvement of the dorsum nasi. She showed a depression of the dorsum nasi and the region corresponding to the right upper lateral cartilage. An open rhinoseptoplasty was performed, with placement of an Integra™ layer folded on itself into two sheets on the



**Fig. 3** Patient with excessive resection in the dorsum due to a previous surgery. Integra™ was folded into two sheets in the dorsum nasi



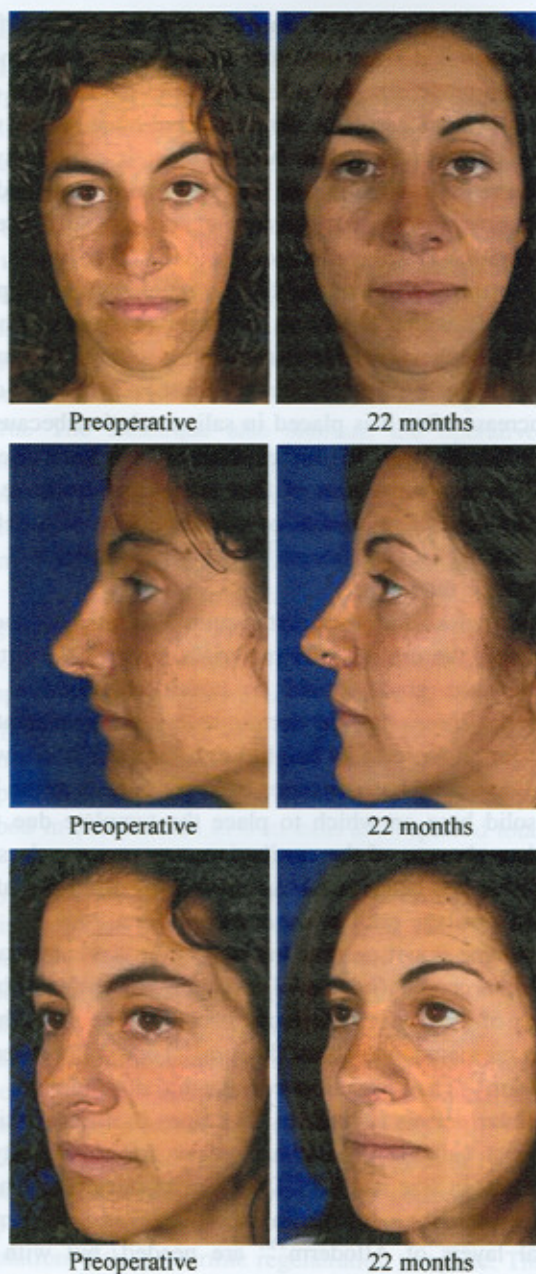osteocartilaginous dorsum and one sheet in the right upper lateral cartilage (Fig. 4).

#### Case 4

A 44-year-old man with a history of nasal trauma in childhood was affected by sequelae of rhinoplasty. At his

examination, he showed respiratory difficulty, deformity of the dorsum nasi with a visible edge of the costal cartilage graft from the previous rhinoplasty, a very marked supratip break, minimum depression in the right upper lateral cartilage, and a large synechia between the nasal septum and the lower concha in the right nasal nostril. A rhinoseptoplasty was performed including a bridle resection, costal



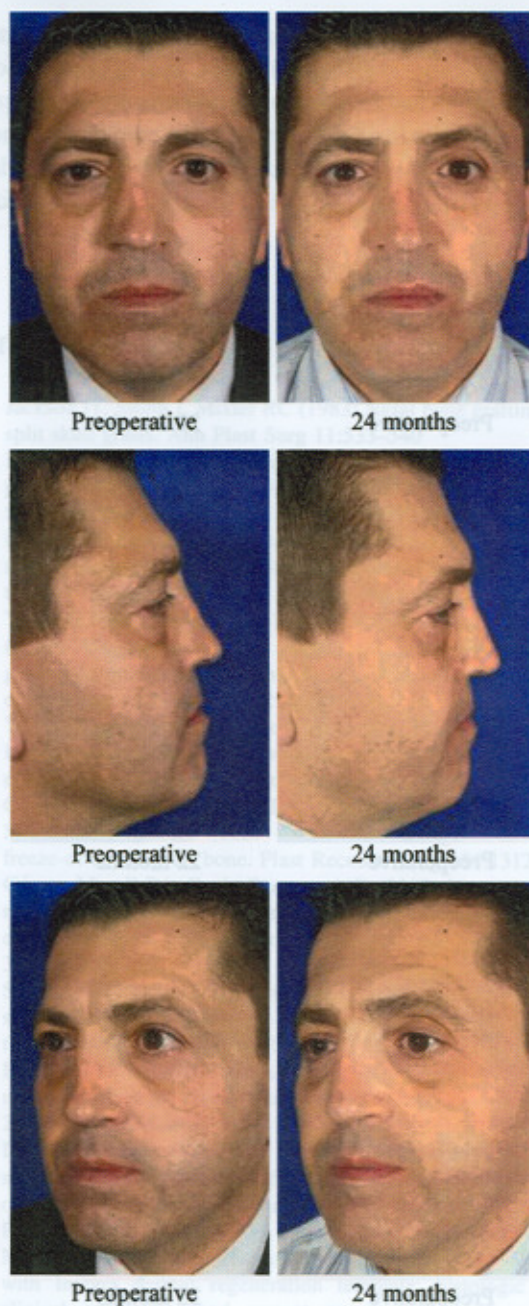

**Fig. 4** Patient with sequelae of a previous rhinoplasty in the dorsum and right upper lateral cartilage. Two sheets of Integra™ were used in the dorsum nasi and one in the depression of the area of the right upper lateral cartilage

graft edge resection, osteotomies, and a sheet of Integra™ folded in a double layer in the entire dorsum nasi area (Fig. 5).

#### Case 5

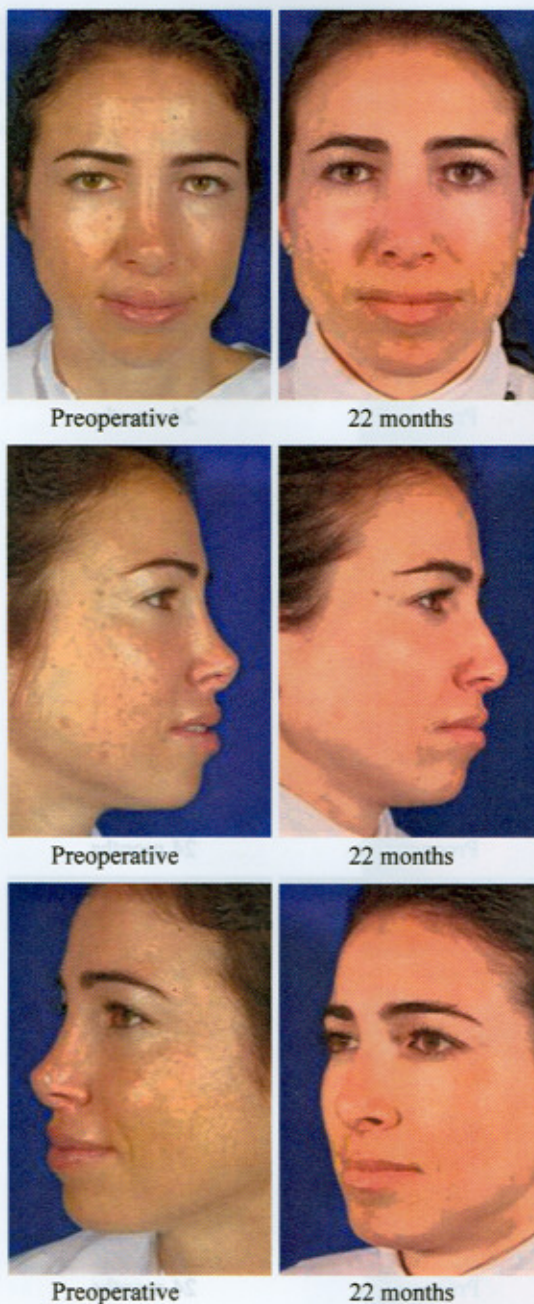A 33-year-old woman had a history of rhinoplasty sequelae. An open rhinoplasty was performed. First, the existing fibrosis was removed. Then, tip reconstruction with a



**Fig. 5** Patient with a previous record of traumatic nose and sequelae of rhinoplasty. The deformity caused by the costal graft from the previous rhinoplasty has been corrected. Lateral osteotomies have been performed to close an open roof the deformity, and two layers of Integra™ have been placed in the whole dorsum nasi

columella strut and a Peck graft was performed. A dorsal reconstruction with Permacol™ (Covidien PLG, Dublin, Ireland) (porcine dermis) also was performed, which was reabsorbed in a few months. Next, a lyophilized bone was placed, which also was reabsorbed eventually. Finally, Integra™ was used for the same purpose (Fig. 6).





**Fig. 6** Patient with sequelae of a previous rhinoplasty. A tip reconstruction was performed, and three layers of Integra<sup>TM</sup> were used to fill the dorsum deformity

## Discussion

We believe that the dermic regeneration template (Integra<sup>TM</sup>) can be used successfully as a filler in primary or secondary rhinoplasties when the material is handled properly. As mentioned earlier, we use demineralized bone matrix activated with PGFs in our protocol for the correction of dorsum nasi defects when the osseous dorsum nasi or the nasofrontal angle needs only moderate augmentation.

When it is necessary to correct more important defects of the osseous dorsum nasi that need a greater volume of correction or defects that affect not only the osseous dorsum but also the cartilage, demineralized bone matrix with PGF is not the best option two reasons: It cannot give a large increase in volume, and an osseous bed is needed for its placement and the consequent process of osseous regeneration. For these reasons and in these cases, we prefer to use a sheet of the dermic regeneration template (Integra<sup>TM</sup>), which allows us to obtain constant regeneration of autologous dermic tissue with a suitable thickness.

The thickness of the Integra<sup>TM</sup> sheet is 2 mm and does not increase after it is placed in saline solution because it comes already wet. In our experience, we have used it folded up to a maximum of four times, and we have not seen any case of resorption or overcorrection of a defect. Therefore, we can use Integra<sup>TM</sup> to correct defects 8–2 mm in height or thickness.

Nevertheless, for cases that require a significant amount of volume, the use of other materials, such as the autologous osseous graft, should be considered because our experience shows that the dermic regeneration template is useful for an increase in height up to 8 mm if it is always placed on a solid base. In cases of larger defects or the lack of a solid base on which to place the template due to a complete absence of the cartilaginous or osseous dorsum, we believe it is better to use an autologous osseous graft or a costal cartilage graft to solve the problem.

If volume is not needed, but only more thickness to the entire nasal contour (in cases of very thin skins to avoid show-through of the osteocartilaginous structure), we use either a dermis regeneration template (Integra<sup>TM</sup>) or a cellular dermis (Alloderm<sup>TM</sup>) and place it over the entire dorsum nasi.

Cellular dermis (Alloderm<sup>TM</sup>) comes in different sizes. The most suitable Alloderm<sup>TM</sup> sheet for rhinoplasty is 2 × 4 mm in size and 0.17–0.99 mm in thickness. Therefore, to obtain the same thickness as one layer of Integra<sup>TM</sup>, several layers of Alloderm<sup>TM</sup> are needed, but with the inconvenience that its manipulation makes correct and homogeneous placement inside the nose difficult.

Alloderm<sup>TM</sup> can provide a maximum dorsal augmentation of 3 mm and has a partial absorption of 10–30% of the volume [13, 14], especially over the dorsum in thin-skinned patients. It should be noted that although Alloderm<sup>TM</sup> is dermis, it still is a foreign material because it is a cadaver dermal graft.

This the reason why Alloderm<sup>TM</sup> currently is used solely in cases that require only a thicker cover/coat of the nose with just one layer of Alloderm<sup>TM</sup>. The big advantage of Integra<sup>TM</sup> over the other options (e.g., Alloderm<sup>TM</sup>, fascia lata allografts) is that only Integra<sup>TM</sup> is completely reabsorbed and replaced by autologous tissue because it regenerates the patient's own dermis.



Dermal autologous grafts also have a range of reabsorption [15, 16] compared with diced cartilage wrapped in Surgicel [17] or fascia [18], which has no reabsorption, as confirmed histologically [19]. However, they have the disadvantage of a donor-site scar as well as visibility and junctional stepoffs [18].

The technique is simple, and the tridimensional matrix of the dermic regeneration template is completely reabsorbed and replaced by autologous dermis. It also avoids behavior as a foreign body and stops the possibility of granulomas [11]. The hospital stay with this technique is shorter than that needed with the use of autologous osseous grafts. The technique also shortens the operative time significantly by eliminating graft harvest. The patients avoid scars in the donor area needed to obtain the osseous or cartilaginous graft; and they also have an easier and less painful postoperative period. We also assessed positively the natural touch and the impossibility of implant migration.

Our experience confirms that the dermic regeneration template achieves steady results during a 27-month follow-up period. We believe this follow-up time is sufficient to demonstrate that the results are steady in terms of reabsorption because the material used is completely reabsorbed in a maximum of 6 months and replaced totally by the patient's own tissue. Only long-lasting edema could vary the final result. For this reason, although the results during a follow-up period longer than 2 years are encouraging, we will revise our evaluation later for the best understanding of this technique's effectiveness.

Besides, it is already demonstrated that the thickness obtained with the same material for other indications such as cranial osseous defects, injuries, and burns remains steady, as the medical literature shows [12, 20]. It has an advantage over other techniques (autologous or lyophilized bone), which result in a certain level of long term reabsorption. No secondary revision was needed after augmentation with the dermic regeneration template. The cost of Integra<sup>TM</sup> is something to be considered before the surgery is planned, and the number of layers needed directly affects the final cost of the product used.

## Conclusion

The dermis regeneration template (Integra<sup>TM</sup>) is an alternative filler to be considered in rhinoplasty, primarily for cases with significant defects in the dorsum nasi due to trauma or secondary rhinoplasties. We highlight the fact that Integra<sup>TM</sup> is easy to handle and versatile. It can be folded into several layers onto itself. However, it is mandatory that the template not be too compressed in the implanted bed because it can collapse the porous matrix,

restricting the fibroblast migration necessary to create the neodermis [7]. It is a simple technique that shortens the hospital stay and avoids postsurgical complications such as morbidity of the donor area; migration, visibility and reabsorption of the implant, and reaction to a foreign body. Satisfaction has been very high and steady for all patients.

## References

- Jackson IT, Smith J, Mixer RC (1983) Nasal bone grafting using split skull grafts. *Ann Plast Surg* 11:533–540
- Inanli S, Sari M, Baylancicek S (2007) The use of expanded polytetrafluoroethylene (Gore-Tex) in rhinoplasty. *Aesthetic Plast Surg* 31:345–348
- Bottini DJ, Gentile P, Donfrancesco A, Fiumara L, Cervelli V (2008) Augmentation rhinoplasty with autologous grafts. *Aesthetic Plast Surg* 32:136–142
- Tosun Z, Karabekmez FE, Keskin M, Duymaz A, Savaci N (2008) Allogeneous cartilage graft versus autogenous cartilage graft in augmentation rhinoplasty: a decade of clinical experience. *Aesthetic Plast Surg* 32:252–260
- Yilmaz M, Vayvada H, Menderes A, Mola F, Atabey A (2007) Dorsal nasal augmentation with rib cartilage graft: long-term results and patient satisfaction. *J Craniofac Surg* 18:1457–1462
- Clark RP, Wong G, Johnson LM, Hagge RJ, Ciminello F, Lee J, Stone KI, Clark IA (2009) Nasal dorsal augmentation with freeze-dried allograft bone. *Plast Reconstr Surg* 124:1312–1325
- Gómez Morell PA, Paolo Domenech R (2007) Uso del regenerador dérmico Integra como material de relleno para el tratamiento de defectos del contorno corporal. *Cir Plast Iberolatinoam* 33:195–200
- Stern R, McPherson M, Pharm D, Longaker T (1990) Histologic study of artificial skin used in the treatment of full-thickness thermal injury. *J Burn Care Rehab* 11(1):7–13
- Hembach D, Luterman A, Burke J (1988) Artificial dermos for major burns: a multicenter randomized clinical trial. *Ann Surg* 208:313
- Dantzer E, Queruel P, Salier L (2001) Integra, a new surgical alternative for the treatment of massive burns: clinical assessment of acute surgery and reconstructive surgery on 39 cases. *Ann Chir Plast Esth* 46:173–189
- Moiemen N, Vlachou E, Staiano J (2006) Reconstructive surgery with Integra dermal regeneration template: histologic study, clinical evaluation, and current practice. *Plast Recon Surg* 117:160s–174s
- Sheridan R, Hegarty M, Tompkins R, Burke J (1994) Artificial skin in massive burns: results to ten years. *Eur J Plast Surg* 17:91–93
- Gryskiewicz JM, Rohrich RJ, Reagan BJ (2001) The use of Allograft for the correction of nasal contour deformities. *Plast Reconstr Surg* 107:561–570
- Gryskiewicz JM (2005) Waste not, want not: the use of AlloDerm in secondary rhinoplasty. *Plast Reconstr Surg* 116:1999–2004
- Karaaltın MV, Orhan KS, Demirel T (2009) Fascia lata graft for nasal dorsal contouring in rhinoplasty. *J Plast Reconstr Aesthet Surg* 62:1255–1260
- Erdogan B, Tuncel A, Adanali G, Deren O, Ayhan M (2003) Augmentation rhinoplasty with dermal graft and review of the literature. *Plast Reconstr Surg* 111:2060–2068
- Erol OO (2000) The Turkish delight: a pliable graft for rhinoplasty. *Plast Reconstr Surg* 105:2229–2241



18. Daniel RK (2008) Diced cartilage grafts in rhinoplasty surgery: current techniques and applications. *Plast Reconstr Surg* 122:1883–1891

19. Calvert JW, Brenner KB, Da Costa-Iyer M, Evans GRD, Daniel RK (2006) Histological analysis of human diced cartilage grafts. *Plast Reconstr Surg* 118:230

20. Palao R, Gómez P, Huguet P (2003) Burned breast reconstructive surgery with Integra dermal regeneration template. *Br Plast Surg* 56:252

References

1. Jackson TT, Smith J, Minton RC (1983) Local bone grafting using split skull graft. *Am J Plast Surg* 11:232–239

2. Jankovic S, et al. (2007) A comparison of diced cartilage and autologous fat for nasal tip augmentation. *Arch Facial Plast Surg* 9:442–445

3. Berman BI, Gantz H, Hirschman A, Frenkel E, Gurevitz V (2007) Dermal regeneration template for nasal tip augmentation. *Arch Facial Plast Surg* 9:442–445

4. Tansik A, Karadas H, Karadas M, Toprak A, Karadas N (2007) Allogeneic cartilage and versus autologous cartilage graft in augmentation rhinoplasty: a decade of clinical experience. *Arch Facial Plast Surg* 9:442–445

5. Yildiz M, Yavuz H, Muezzin F, Akbulut F, Akbulut A (2007) Dermal regeneration template for nasal tip augmentation: a retrospective study. *Arch Facial Plast Surg* 9:442–445

6. Cui W, Wang D, Johnson LA, Higgins BA, Choudhry F, Lee J, et al. (2009) A 10-year follow-up of nasal augmentation with diced-thin allograft bone. *Plast Reconstr Surg* 123:1312–1322

7. Gómez P, Palao R, Palao D, Gómez P (2007) The use of autologous fat for nasal tip augmentation: a retrospective study. *Arch Facial Plast Surg* 9:442–445

8. Saini A, Muezzin F, Karadas M, Karadas N, Karadas H (2007) A study of autologous fat for the treatment of the dorsum of the nasal bridge. *Arch Facial Plast Surg* 9:442–445

9. Hirschman A, Gantz H (1998) Allogeneic cartilage for nasal tip augmentation: a retrospective study. *Arch Facial Plast Surg* 9:442–445

10. Gantz H, Gantz H (2001) The use of autologous fat for the treatment of the dorsum of the nasal bridge: a retrospective study. *Arch Facial Plast Surg* 9:442–445

11. Muezzin F, Karadas H (2007) A study of autologous fat for the treatment of the dorsum of the nasal bridge: a retrospective study. *Arch Facial Plast Surg* 9:442–445

12. Gantz H, Gantz H (2001) The use of autologous fat for the treatment of the dorsum of the nasal bridge: a retrospective study. *Arch Facial Plast Surg* 9:442–445

13. Gantz H, Gantz H (2001) The use of autologous fat for the treatment of the dorsum of the nasal bridge: a retrospective study. *Arch Facial Plast Surg* 9:442–445

14. Gantz H, Gantz H (2001) The use of autologous fat for the treatment of the dorsum of the nasal bridge: a retrospective study. *Arch Facial Plast Surg* 9:442–445

15. Gantz H, Gantz H (2001) The use of autologous fat for the treatment of the dorsum of the nasal bridge: a retrospective study. *Arch Facial Plast Surg* 9:442–445

16. Gantz H, Gantz H (2001) The use of autologous fat for the treatment of the dorsum of the nasal bridge: a retrospective study. *Arch Facial Plast Surg* 9:442–445

17. Gantz H, Gantz H (2001) The use of autologous fat for the treatment of the dorsum of the nasal bridge: a retrospective study. *Arch Facial Plast Surg* 9:442–445

Surgical [17] or laser [18] which has no need for donor site. However, they have the disadvantage of a donor site scar as well as visibility and functional aspects [19]. In our study, we used the dermal regeneration template as a completely new method and replaced by autologous fat. It also avoids the donor site scar and the possibility of infection [21]. The hospital stay with this technique is shorter than that needed with the use of autologous fat grafts. The technique also shortens the operative time significantly by eliminating graft harvest. The patient would return to the donor site needed to obtain the autologous fat graft and they should have no donor site scar or pain postoperative period. We also assessed positively the natural touch and the possibility of implant migration after a certain time of postoperative.

Our experience confirms that the dermal regeneration template achieves steady results during a 23-month follow-up period. We believe this follow-up time is sufficient to demonstrate that the results are steady in terms of volume reduction because the template used is completely stable for a maximum of 6 months and replaced usually by the patient's own tissue. Only long-lasting volume could very far from results for this reason, although the results during a follow-up period longer than 2 years are common, we will never see evolution later for the best understanding of this technique's effectiveness. In our study, it is clearly demonstrated that the thickness obtained with the same material for other indications such as cranial, axillary, dorsal, inguinal, and breast fat grafts, as the thickness reduction shows [13, 20]. It has an advantage over other techniques (autologous or allogeneic fat) which result in a certain level of long-term stability. No secondary revision was needed after fat graft placement with the dermal regeneration template. The use of Integra<sup>TM</sup> is interesting to be considered before the surgery is planned, and the number of layers needed directly affects the final cost of the product used.

and out in market will have advantages [4, 5]. Similar Conclusion: Integra<sup>TM</sup> has been a choice for treatment of a facial scar. It is a choice if it is used in a certain manner. The dermal regeneration template (Integra<sup>TM</sup>) is an effective alternative to be considered in rhinoplasty, primarily for cases with significant defect in the dorsum and the tip. The main or secondary rhinoplasty. We highlight the fact that Integra<sup>TM</sup> is easy to handle and versatile. It can be placed into several layers onto itself. However, it is important that the template not be too compressed in the implanted bed because it can collapse the previous matrix

